

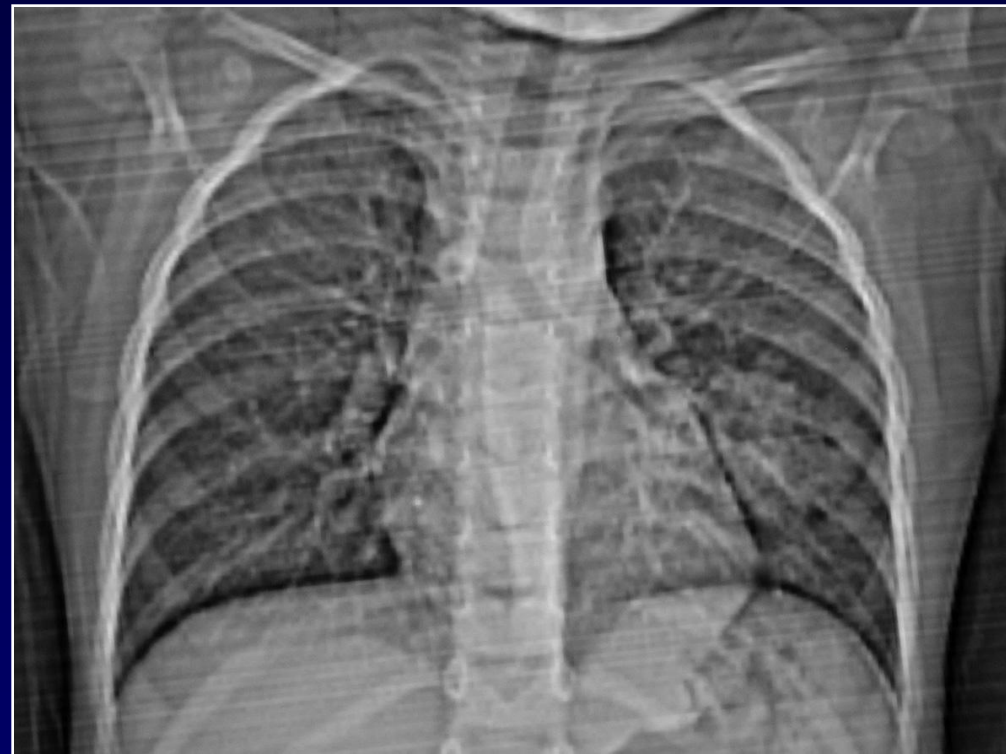

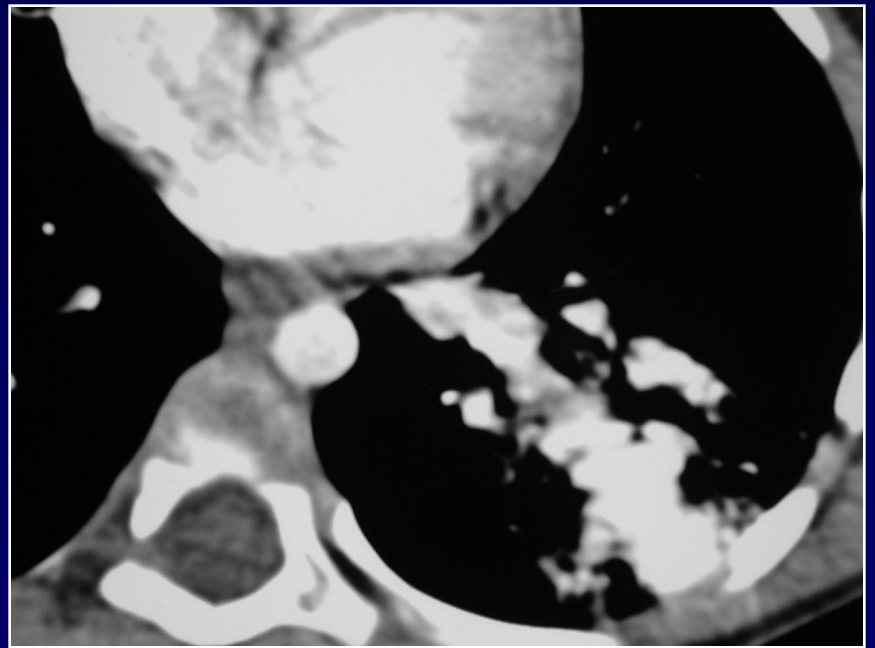
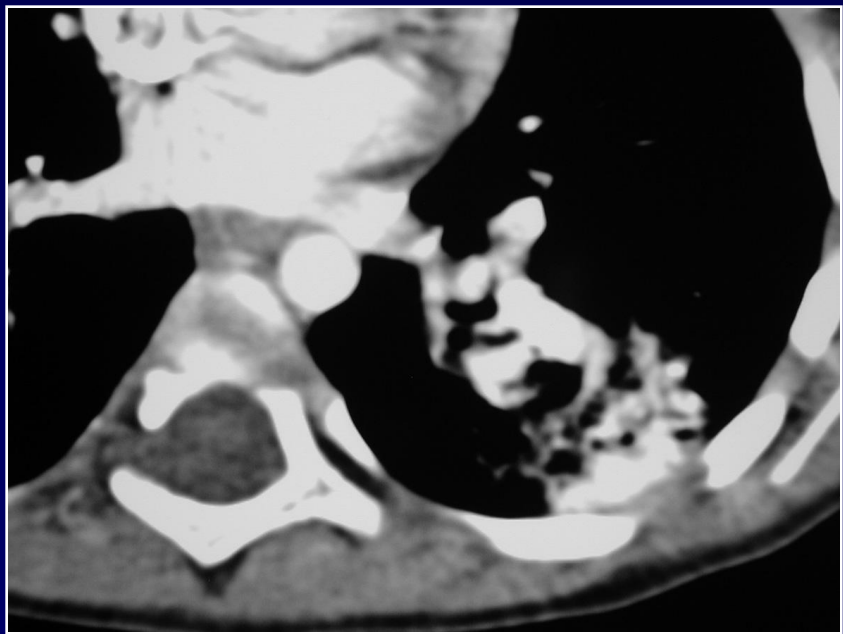
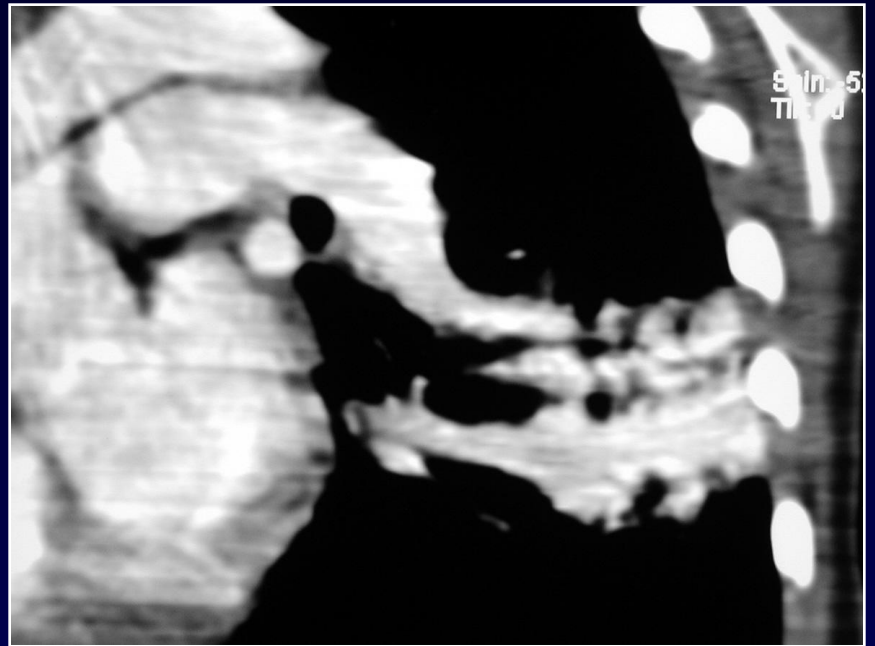
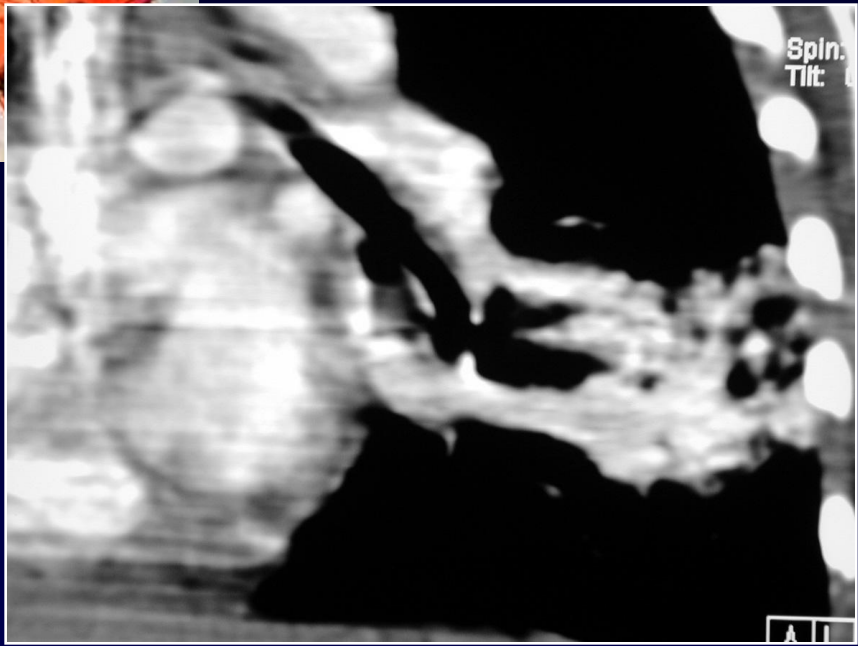
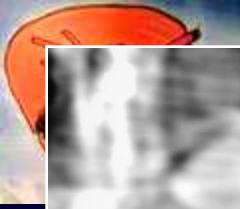J GIRON

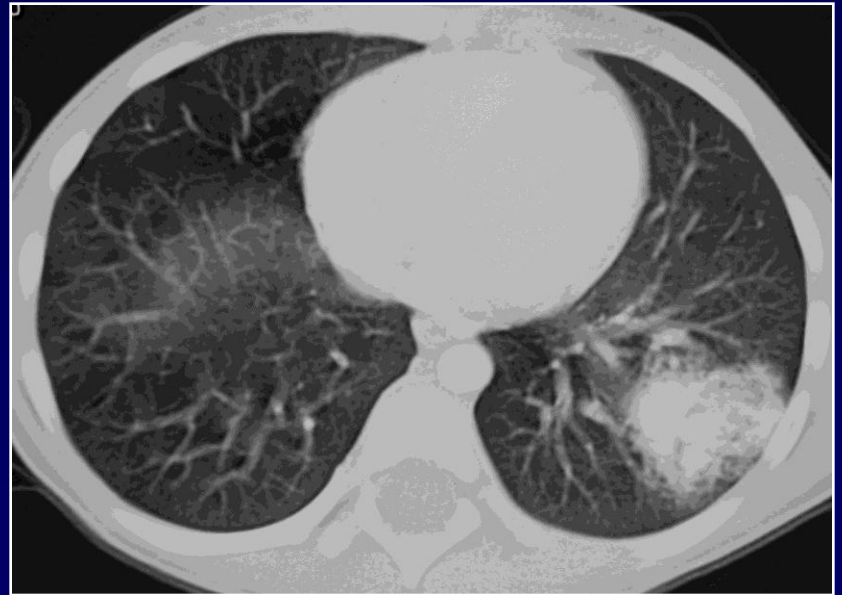
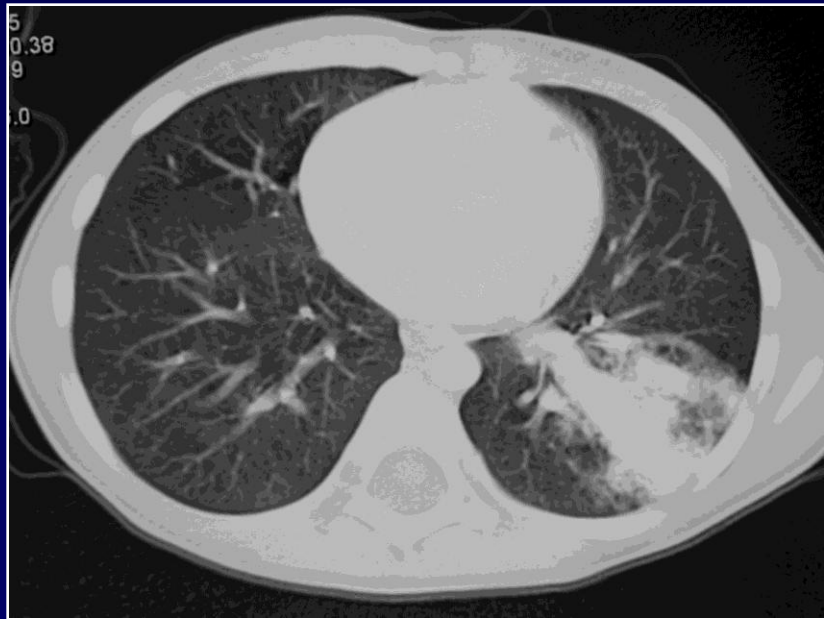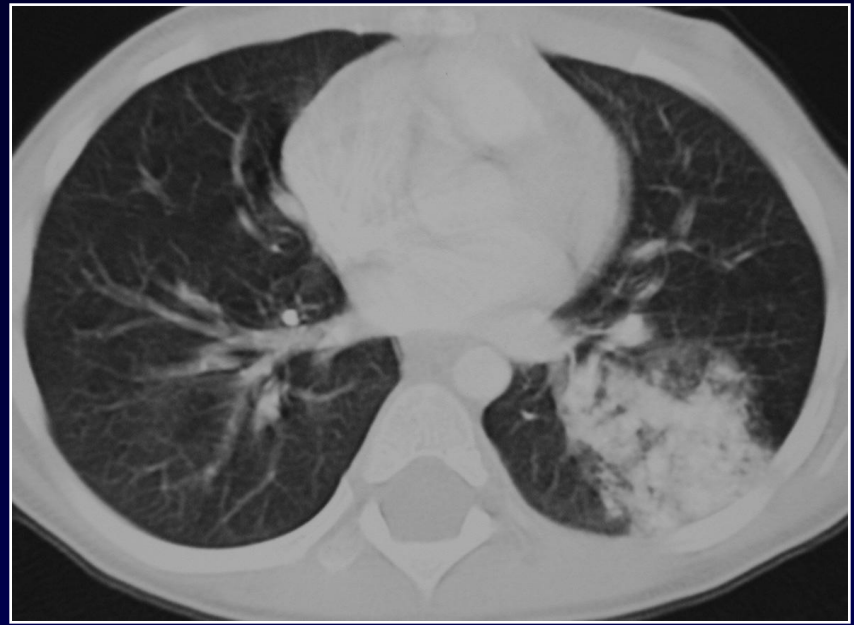
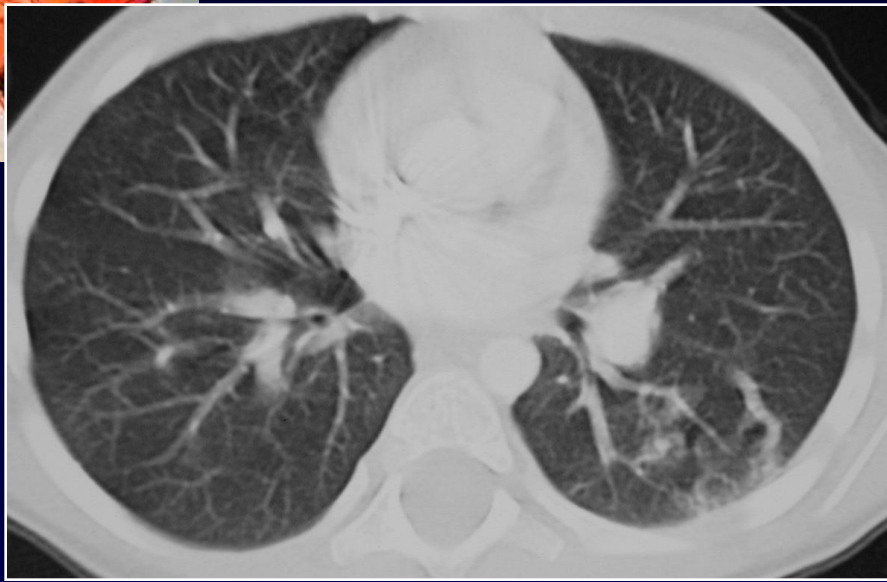

Pauline, 2 ans et demi

**Cyanose depuis la naissance
avec dyspnée**

**Aspect radiographique de
pneumopathie traînante de
la base gauche**









Anomalie artério-veineuse lobaire inférieure gauche

Traitement: chirurgie ou embolisation?



Diagnostic ?



Diagnostic

C